


The effects of Pyrantel-Oxantel on the *Dipylidium caninum* tapeworm: An *in vitro* study



Jair Millán-Orozco ^{a†*},

Jersson Millán-Orozco ^{a‡},

Miguel Ángel Betancourt-Alonso ^b,

América Ivette Barrera-Molina ^c,

María Soledad Valledor ^d,

Virginia Méndez ^d,

Alejandra Larrea ^d,

Martín Sebastián Lima ^d,

Javier Morán-Martínez ^e,

Nadia Denys Betancourt-Martínez ^e,

Liliana Aguilar-Marcelino ^f,

^a Universidad Autónoma del Estado de Morelos, Facultad de Ciencias Agropecuarias. Av. Universidad No. 1001, Col. Chamilpa . 62209, Cuernavaca, Morelos, México.

^b Escuela de Medicina Veterinaria y Zootecnia en Pequeñas Especies, Federación Canófila Mexicana A.C. Ciudad de México, México.

^c Universidad Autónoma del Estado de Morelos, Facultad de Nutrición. Cuernavaca, Morelos, México.

^d Universidad de la República. Facultad de Veterinaria. Montevideo, Uruguay.

^e Universidad Autónoma de Coahuila. Facultad de Medicina. Torreón, Coahuila, México.

^f Instituto Nacional de Investigaciones Forestales Agrícolas y Pecuarias. Centro Nacional de Investigación Disciplinaria en Salud Animal e Inocuidad, Jiutepec, Morelos, México.

[¥] Universidad Autónoma Agraria Antonio Narro. Departamento de Ciencias Médico Veterinarias. Torreón, Coahuila, México.

[‡] Asociación de Médicos Veterinarios Zootecnistas Especialistas en Bovinos de la Comarca Lagunera, A.C. Gómez Palacio, Durango, México.

*Corresponding author: jmillan.orozco@uaaan.edu.mx

Abstract:

The present study aimed to evaluate, *in vitro*, the cestocidal effect of Pyrantel-Oxantel on the *Dipylidium caninum* tapeworm. Each intestine sample was obtained by means of a transversal incision of the abdominal area of each euthanized canine subject, individually dissected via longitudinal incision, and examined for the presence of *D. caninum*. An optical microscope was used to identify and verify proglottid morphology and viability based on its macroscopic appearance. The cestocidal effects of Pyrantel-Oxantel (75 mg pyrantel pamoate; 75 mg oxantel pamoate) were assessed in adult tapeworms (treated group, n= 21; control group, n= 21) placed on Petri dishes and incubated at 37 °C. One-hour post-incubation, the *D. caninum* cestodes treated with Pyrantel-Oxantel presented a 28 % decrease ($P=0.001$) in motility, which rose to a 52 % ($P=0.0001$) decrease by the end of the second hour. The control group ($P=0.0001$) presented 55.7 % motility for at least the first six hours of incubation and 4.2 % ($P=0.001$) motility by the end of the study, while 0 % motility was observed in the treated group by the end of the study. Pyrantel-Oxantel had a lethal effect ($P=0.0001$) on adult *D. caninum*, with 100 % mortality observed 6 h after *in vitro* post-incubation, while the control group presented 55.7 % viability after the same time period. In addition, Pyrantel-Oxantel reduced ($P=0.001$) tegument thickness by 42.5 % ($10.24 \pm 0.21 \mu\text{m}$), while this was $17.81 \pm 0.33 \mu\text{m}$ for the control group. The results of this study indicate that Pyrantel-Oxantel has a therapeutic effect on the presence of *D. caninum*, inducing both a reduction of the tegument thickness and increased mortality.

Key words: *Dipylidium caninum*, Helminths, Zoonosis, Motility, Morphology, Cestocidal effect.

Received: 11/08/2018

Accepted: 09/11/2020

Dipylidium caninum (*D. caninum*) is the causal agent of dipilidiasis, a parasitological disease caused by the adult cestode in dogs, cats, foxes, coyotes, and other wild carnivores⁽¹⁻⁷⁾ and well known as a zoonotic disease affecting humans^(8,9). The control of cestodes with potential zoonotic risk for pet animals is of great importance for public health worldwide^(2,10,11) given the close contact both dogs and cats have with humans⁽¹²⁾, with the risk of infection even higher in children^(8,9). The adult *D. caninum* cestode grows to a length of 50 cm, while its macroscopic structure has the appearance of rosary beads or a grouping of cucumber seeds⁽¹³⁾. Unlike nematodes, cestode parasites do not have a digestive system and grow from proliferating cells in the neck, producing several hundred segments known as proglottids and obtaining food via the tegument or body wall⁽¹³⁾. Located in the small intestine of the host, *D. caninum* absorbs digested material and obtains the nutrients necessary for survival, reproducing without the difficulty undergone by other parasites, because, as a hermaphrodite parasite, it forms gravid proglottids full of infective eggs via continuous differentiation^(9,14,15).

Pyrantel (E-1,4,5,6-tetrahydro-1-methyl-2-pyrimidine) is an imidazothiazole anti-helminthic derived from the tetrahydropyrimidines and used widely by veterinarians on small species (dogs and cats), given its wide spectrum of action against mature and immature gastrointestinal parasites that infect domestic animals⁽¹⁶⁾. Oxantel (1-methyl-2-(3-hydroxyphenyl-ethenyl) 1,4,5,6-tetrahydropyrimidine) is an *m*-oxyphenol derivative of pyrantel⁽¹⁷⁾ that activates the N-subtype, a nicotine and methyridine-sensitive subtype. Pyrantel activates the L-subtype, a levamisole- and pyrantel-sensitive subtype, which explains why differences in their target nematodes have been reported⁽¹⁶⁾.

Tetrahydropyrimidines comprise a wide variety of pyrantel, morantel, and oxantel salts, all of which have nicotinic agonist effects which alter the parasite's neuromuscular system, affecting muscular contraction and causing tonic paralysis. The nicotinic acetylcholine receptors (nAChRs) are essential to the parasite's nervous function, presenting a different distribution and physiology than that found in mammals⁽⁹⁾. Nicotinic agonist anti-helminthics act on the nicotinic acetylcholine in the parasite's neuromuscular junction, causing neuromuscular depolarization and spastic paralysis^(18,19). Parasite nAChRs have five glycoprotein subunits located around a central ion channel⁽²⁰⁾, comprising a pentameric ligand-gated ion channels, which is a structure with significant pharmacological effects⁽¹⁶⁾. Moreover, nAChRs are functionally diverse due to their extensive gene families encoding subunits and three pharmacological sub-populations of receptors⁽¹⁶⁾. The activation of the acetylcholine receptor in nematodes has been divided into three pharmacological subtypes according to the degree of nicotinic affinity^(21,22), characterized and defined as follows: the N-subtype, with significant sensitivity to nicotine, methyridine, and oxantel; the L-subtype, with affinity to levamisole and pyrantel; and, the B-subtype, with a greater sensitivity to bephenium.

Pyrantel's mechanism of action functions by blocking muscular excitation via the activation of an agonist of the nAChR^(18,19), altering the neuromuscular system and, thus, provoking muscular contraction and paralysis, which result in the death of the parasite⁽⁹⁾. Oxantel (*m*-oxyphenol) has been shown to be effective against gastrointestinal nematodes of great impact on both animal and public health^(23,24). While the effect of pyrantel-oxantel (P-O), as a combined treatment, on nematode parasites has been reported previously⁽²⁵⁾, there are no scientific reports on the effects of a P-O combination, either *in vivo* or *in vitro*, on motility, tegument thickness, or other anatomical structures in tapeworms. Therefore, the present study aimed to evaluate the *in vitro* cestocidal effect of P-O on the motility and tegument thickness of adult *Dipylidium caninum* cestodes and to describe the histological changes in the organisms' gravid proglottids.

All the euthanasia procedures applied in the present study were performed following the guidelines recommended and approved by the Ethics Committee for Animal Experimentation of the Faculty of Agricultural and Livestock Sciences at the Autonomous University of the State of Morelos and the Code of Ethics of the World Medical Association (Declaration of Helsinki).

Two hundred and sixty-six (266) naturally infected stray dogs were sampled at the Canine and Feline Control Center in the municipality of Tlahuac, Mexico City, after capture by the municipal animal control brigade. The animals were euthanized by authorized personnel via an anesthetic overdose, with the small intestine of each subject then obtained via a transversal incision on their abdomen. The small intestines obtained, still connected via the gastroduodenal and ileocecal valves, were stored in plastic bags, labelled with progressive numbers, and transported to the Animal Production Laboratory at the Faculty of Agricultural and Livestock Sciences at the Autonomous University of the State of Morelos, located in the city of Cuernavaca⁽²⁶⁾.

Each intestine sample was individually dissected via longitudinal incision and examined for the presence of *D. caninum* cestodes, which were identified via the macroscopic appearance of the proglottids and allocated using an optical microscope to verify their morphology⁽²⁷⁾. Direct observation was carried out under a microscope to determine the viability of the parasites at 40X objective, with cestodes presenting full motility for a one-minute period considered viable for subsequent experimentation⁽²⁸⁻³⁰⁾.

The cestocidal effect of P-O on adult parasites was assessed (treated group (P-O), n= 21; control group (CG), n= 21), with the individuals placed in 90x60 mm Petri dishes containing 10 mL of RPMI (Roswell Park Memorial Institute) 1640 and incubated at 37 °C for 10 h. Distilled water and PMSF (phenylmethane sulfonyl fluoride) were used as a protease inhibitor vehicle for the control group, in order to maintain the structural anatomy and physiology of the cestodes. For the treated group, a commercial deworming drug (75 mg

Pyrantel Pamoate and 75 mg Oxantel Pamoate (Vermiplex), Holland Animal Health Laboratories, Jiutepec, Morelos, Mexico) was used, wherein macerated tablets were added to distilled water in the Petri dishes.

After incubation, direct observation was carried out in a stereoscopic microscope every hour to determine the cestocidal effects. The motility test was conducted in triplicate⁽²⁶⁾, wherein cestode motility was evaluated on scale of 0 to 5, as follows: 0 indicated completely motionless tapeworms that did not respond to manual stimulation; 1 indicated movement only when prodded; 2 indicated spontaneous activity, but solely at either end of the organism, namely the scolex and the end of strobila; 3 indicated slow and spontaneous activity throughout the assessment; 4 indicated that the subject was more active; and, 5 indicated that the subject was highly active⁽²⁸⁻³⁰⁾.

Adult parasite segments (gravid proglottids) were obtained and fixed in 10% paraformaldehyde and kept under refrigeration at 4 °C until the histological procedure was carried out. In order to observe the histological structure and quantify the height of the secretory epithelium and the thickness of the lamina propria, tissue sections were obtained and placed on glass slides previously treated with poly-l-lysine. The paraffin was removed from the sections with xylol, hydrated with alcohols of different concentrations, and made permeable with 0.1% triton X-100 in sodium citrate for 20 min, while endogenous peroxidase activity was then inhibited by incubating the tissue for 25 min in a 0.3% H₂O₂ solution at an ambient temperature. The preparations were washed with a phosphate buffer solution (PBS1X) and marked with a hydrophobic pencil around the tissue⁽³¹⁻³³⁾. *D. caninum* cestode segments were processed, obtaining 5- μ m semi-serial sections. Hematoxylin and eosin staining was used to evaluate the histological structure and tegument thickness⁽²⁷⁾. For each histological section, six microscope fields were observed using a 40X objective, while six tegument thickness measurements were carried out using the Motic 2.0 image analyzer and then photographed^(26,27).

The experimental data corresponding to *in vitro* motility observations were analyzing using a Z-test, while the tegument thickness measurements were compared via a Student's t-test⁽³⁴⁾. Differences were considered statistically significant when $P < 0.05$, while the *in vitro* motility results are expressed as a percentage and the histology results are expressed as both mean and standard error.

Results for the efficacy of P-O in terms of the motility of *D. caninum* parasites are available in Table 1. At the beginning (Hour 0) of the experiment, both groups presented total motion ($P=0.07$). The P-O showed progressive motility reduction (from 72.0 to 4.8 %) from the first to the fifth hour post-incubation, thus achieving a mean hourly reduction of 19 %, while, from hours six to ten, 0 % motility was observed. In the control group (CG), 100 % motility

was observed for the first 2 h post-incubation, while motility reduced from 96.2 to 4.2 % from the third hour to the end of the experiment, giving a mean reduction of 10 % per hour.

Table 1: *In vitro* motility (%) of *Dipylidium caninum* adult cestodes treated with Pyrantel-Oxantel

Groups	Incubation (h)										
	0	1	2	3	4	5	6	7	8	9	10
Pyrantel-Oxantel	100 ^a	72.0 ^a	48.0 ^a	25.0 ^a	15.8 ^a	4.8 ^a	0.0 ^a	0.0 ^a	0.0 ^a	0.0 ^a	0.0 ^a
Control	100 ^a	100 ^b	100 ^b	96.2 ^b	85.3 ^b	72.7 ^b	55.7 ^b	41.5 ^b	31.5 ^b	20.0 ^b	4.2 ^b

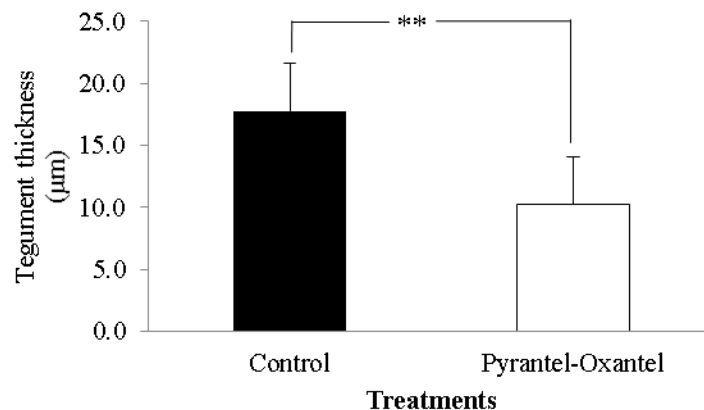
Three replicates were carried out for each group, using one hundred and twenty-six tapeworms.

^{ab} Different letters show significant differences ($P=0.0001$).

A ($P=0.0001$) difference was observed between the treated and CG groups between the first hour and the end of the experiment. In the first hour post-incubation, the motility of the treated group was 72.0 %, while this was 100 % for the CG ($P=0.0001$). Motility of 55.7, 41.5, 31.5, 20.0, and 4.2 % was observed at hours 6, 7, 8, 9 and 10 post-incubation, while 0.0 % motility was observed in the treated group from the sixth hour onward post-incubation ($P=0.0001$).

The effects of P-O on the tegument thickness ($P=0.001$) of adult *D. caninum* cestodes are shown in Figures 1 and 2, wherein P-O reduced tegument thickness by 42.5 % ($10.24 \pm 0.21 \mu\text{m}$) (Figure 2b; grey arrowhead), while this was $17.81 \pm 0.33 \mu\text{m}$ for the CG (Figure 2a; grey arrowhead).

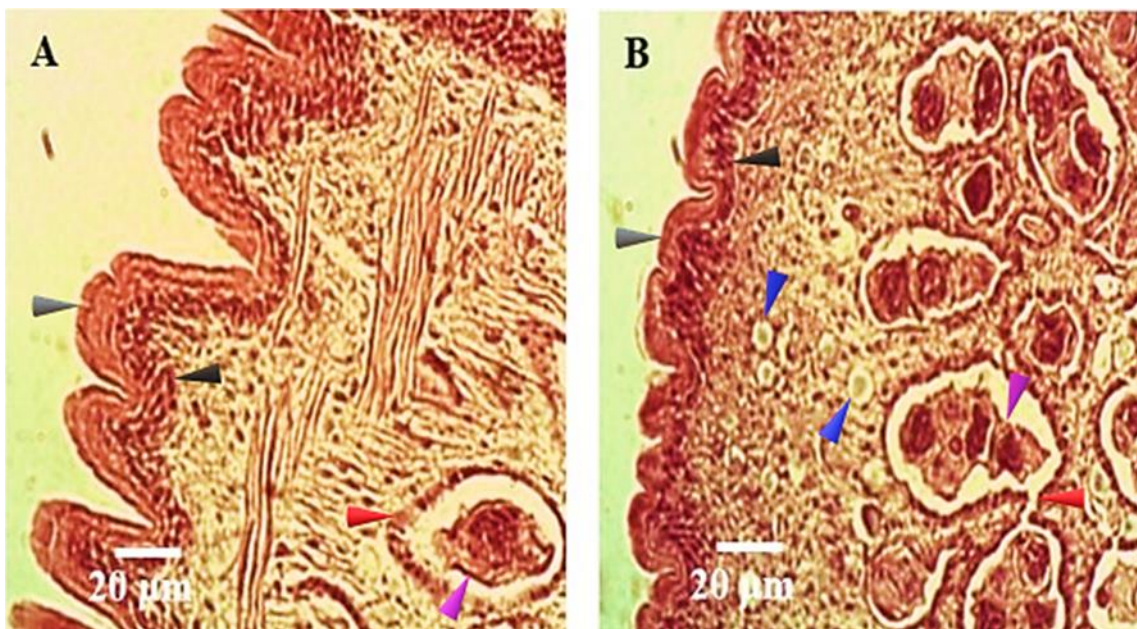
Figure 1: Effect of Pyrantel-Oxantel on tegument thickness (mean \pm SEM) in *Dipylidium caninum* adult cestodes



**Significant differences among groups ($P=0.001$).

The effects of P-O on the general structure of *D. caninum*, as compared to the structure presented by the CG, are shown in Figures 2a and b. A significant finding regarding the histology of the gravid proglottids observed was the concentration of immature calcareous corpuscles (CCs) (black arrowheads) along the surface and near the tegument (Figure 2a, b). In the CG, the immature CCs concentration was higher than that observed in the proglottids treated with P-O (Figure 2a; black arrowhead), while mature CCs were only observed in the P-O group (Figure 2b; blue arrowhead), in which an alteration of the *D. caninum* eggs was also observed. In the group treated with P-O, the morphology and distribution of egg sacs was found to have been altered, while, in the CG, the egg sacs presented a normal morphology and distribution (Figure 2b; purple arrowhead). Finally, the embryophore, vitelline layer, and embryo remained almost completely intact in the CG, while, in the P-O group, such structures were distended (Figure 2a; red arrowhead).

Figure 2: Histological sections of *Dipylidium caninum* tapeworms. Tegument thickness obtained in untreated cestodes (**A**) and those treated with Pyrantel-Oxantel (**B**)



A) Intact tegument thickness (grey arrowhead), immature calcareous corpuscles along the surface and near the tegument (black arrowheads), intact embryophore and vitelline layer (purple arrowhead), and the embryo (red arrowheads). **B)** Reduction in tegument thickness (grey arrowhead), reduction in numbers of immature calcareous corpuscles (black arrowhead), the appearance of mature calcareous corpuscles (blue arrowhead), morphology and distribution of egg sacs (purple arrowhead), embryophore, vitelline layer, embryo, and distended structures (purple and red arrowheads).

The present study shows the effects of P-O on the motility and tegument thickness of adult *D. caninum* cestodes, as well as other histological structures such as calcareous corpuscles, egg sacs, embryophore, the vitelline layer, and the embryo. The motility results obtained in the present study show that P-O has a direct effect on motility, causing 100 % motility

inhibition 6 h post-incubation. Some drugs have a rapid effect on the neuromuscular transmission of some parasites, with, for example, pyrantel and oxantel acting as agonists on the synaptic and extra-synaptic nAChRs in the nematode muscle cells, producing contraction and spastic paralysis⁽³⁵⁾. Early studies evaluated the effects of pyrantel pamoate against *Caenorhabditis elegans*⁽³⁶⁾, while pamoate pyrantel and pamoate oxantel, used in combination, have been found to be effective against *Trichuris muris*⁽³⁷⁾ *Ascaris lumbricoides*⁽³⁸⁾, although this treatment has been found to be ineffective against *Ancylostoma ceylanicum* and *Necator americanus*⁽³⁷⁾. The effects of pyrantel pamoate and oxantel pamoate, 24 h after exposure, include muscle contraction, motility inhibition, and a reduction in the size of the parasite^(36,37), in both infective larvae and adult organisms. While the effects found in these studies concur with the findings of the present study, the P-O treatment applied caused 100% mortality in *D. caninum* tapeworms from the sixth hour post-exposure onward.

The effects of pyrantel pamoate (in paste form) were evaluated in the common horse tapeworm *A. perfoliata*⁽³⁹⁻⁴¹⁾, with a 92-98 % reduction in motility obtained in adult tapeworms after 7 to 16 d of treatment in naturally-infected horses examined at necropsy⁽⁴⁰⁾. Said results concur with the 100% mortality observed *in vitro* in the present study 6 h post-incubation. As pyrantel pamoate salt is practically insoluble in water, it is absorbed at a reduced rate in the gastrointestinal tract, thus enabling it to reach microenvironmental sites on the target parasites more easily than other pyrantel salts such as tartrate, which is more soluble in water and more rapidly absorbed via the gastrointestinal tract, to be then metabolized and excreted in both urine and, in small quantities, in feces⁽⁴⁰⁾. Therefore, the present study shows, *in vivo*, the advantage of the P-O treatment applied in the present study in dogs naturally infected with *D. caninum* tapeworm, as, at least, a lethal effect was observed *in vitro*.

The combination of pyrantel with other drugs has been found to have a limited anthelmintic potential, as observed in *A. ceylanicum* and *N. americanus*⁽³⁷⁾ *in vitro*, which presented antagonistic and non-lethal effects. However, the present study found a synergetic effect and an increased potency via the combination of pamoate pyrantel and pamoate oxantel, obtaining 100 % mortality in the *D. caninum* adult cestode. A similar effect was observed in an earlier study using a combination of embonate pyrantel, embonate oxantel, and praziquantel, obtaining 100 % mortality *in vitro* eight hours post-incubation⁽³³⁾. While the foregoing results concur with those obtained by the present study, these results show 100 % mortality *in vitro* 6 h post-incubation. The effect of P-O observed in the present study is due to the capacity of the drug to remain in microsites on the parasites, thus increasing its absorption by the cestode along the length of the tegument and shortening the time in which it takes effect, thereby increasing mortality.

The tegument is one of the major structures in a cestode, which requires this anatomical feature both for absorbing semi-digested material from the small intestine of the host and improving the cestode's physiological function and reproduction, given that, unlike nematodes, cestodes have no digestive tract. Therefore, the absorption capacity of the tegument in cestodes is higher than that found in nematodes. In relation to the foregoing, during their establishment, helminth parasites produce increased levels of pro-inflammatory cytokines in the host⁽⁴²⁾, producing, in consequence, cachexia.

The present study found that P-O substantially reduced tegument thickness in the *D. caninum* tapeworm. There are reports in the literature of this treatment affecting the tegument to different degrees, causing changes and irreversible morphological damage to the tegument and parenchyma, alterations in muscular organization, the absence of tegumentary microvilli, the loss of membrane cells in subtegumental tissue, the development of a dense granular tegument, and large vacuoles generating a patchy and porous appearance, in the following organisms: the rodent tapeworms *Hymenolepis nana*^(43,44), *Hymenolepis microstoma*⁽⁴⁴⁾, *Taenia taeniformis*^(44,45), *Echinococcus multilocularis*^(44,45), and *Hymenolepis diminuta*^(29,44,45); *Taenia solium* in experimentally-infected hamsters⁽⁴⁶⁾; *Taenia crassiceps*⁽⁴⁷⁻⁴⁹⁾; *Mesocestoides corti*⁽⁵⁰⁾; *Raillietina echinobothrida*⁽⁵¹⁻⁵⁴⁾ in domestic fowl; *Anoplocephala perfoliata*⁽³⁰⁾ in horses; *D. caninum*⁽³³⁾ in dogs, cats, and humans; the trematode *Fasciola hepatica* in rats⁽⁵⁵⁾; *Artyfechinostomum sufrartyfex*⁽⁵⁶⁾ in humans; *Fasciolopsis buski*^(53,56); the gastrointestinal swine nematode *Ascaris suum*⁽⁵³⁾; the gastrointestinal canine hookworm nematode *Ancylostoma ceylanicum*⁽⁵⁷⁾; the gastrointestinal rodent nematodes *Rodentolepis microstoma*⁽⁵⁷⁾, *Trichuris muris*⁽⁵⁸⁾, and *Heligmosomoides polygyrus*⁽⁵⁹⁾; and the parasitic plant nematodes of the genera *Meloidogyne* and *Globodera*⁽⁶⁰⁾. The results of the present study concur with the results mentioned above, such as the reduction (thinning) of the tegument by 42.5 % in *D. caninum* parasites treated with P-O after 6 h of *in vitro* incubation. The effect of this treatment on tegument thickness may be more pronounced in parasites incubated for more than six hours, as shown by the histological results; however, histological results were not obtained from the treated subjects more than 6 h post-incubation.

The present study showed the presence of CCs in gravid segments in both the CG or P-O groups; however, in the P-O group, the number of CCs was lower than that observed in the CG. Biomineralization is a widespread phenomenon in invertebrates, with calcium carbonate one of the most abundant biominerals involved in said process⁽⁶¹⁾. In cestodes, minerals produce CCs, the function of which has been the subject of scientific speculation, with some hypotheses proposed, one of which positing that the CCs represent approximately 10 % of the parasites' body weight and that they are to be commonly found in the parenchyma of many metacestodes and adult cestodes^(61,62). Another hypothesis is that CCs play an important role in detoxification⁽⁶³⁾, as, because they are mainly produced in the absence of oxygen, they are thought to anaerobically buffer acids and serve as a reservoir for inorganic

ions⁽⁶⁴⁾. It should be noted that CCs are, in part, an excretory product that serves to remove metabolic waste from the body by passing through the tegument⁽⁶²⁾. Calcareous corpuscles are composed of an organic base coupled with inorganic substances, such as potassium, sodium, magnesium, silicate, calcium, phosphate⁽⁶¹⁾, and sulfate in different cysticercus larvae and adult cestodes⁽⁶⁴⁾. Their organic base includes DNA, RNA⁽⁶⁵⁾, proteins^(66,67), and glycogen^(46,68). Therefore, in the present study, the decreased number of immature CCs distributed near the tegument in the P-O group was due to both a high level of absorption via the tegument of the *D. caninum* cestodes and the length of *in vitro* incubation. Moreover, the 100 % mortality obtained by the present study is also due to both a loss of the protein and glycogen required by the metabolic process in the cells and a probable disintegration of the organism's DNA.

As few studies have been conducted on the density and location of CCs in different parts of the strobila of *D. caninum* cestodes, Khalifa *et al*⁽²⁷⁾ conducted a comparative histochemical and ultrastructural study to ascertain the differences in the location, distribution, composition, and functions of the CCs of *D. caninum* and *T. taeniaeformis*. The results of the present study in relation to CCs concur with those obtained by Khalifa *et al*⁽²⁷⁾ as the distribution of the CCs was concentrated on the lateral sides of the gravid segments of the *D. caninum* cestode and were affected by the P-O treatment.

Hematoxilin and eosin staining of the gravid segments showed that, in the CG, the *D. caninum* eggs were grouped in sacs as observed by Khalifa *et al*⁽²⁷⁾ while the P-O group presented signs of morphological alterations, such as distention of the eggs, embryophore, embryo, and vitelline layer. While few studies have observed the structure of the gravid segments of *D. caninum*, Peña *et al*⁽³³⁾ observed the effects of the toxins of *B. thuringiensis* on *D. caninum*, with their results concurring with those of the present study in showing effects on motility, tegument thickness, and the eggs, effects which reduce the percentage of motility, thin the tegument, and damage the organism's eggs. However, Peña *et al*⁽³³⁾ used a commercial drug containing pyrantel embonate, oxfantel embonate and praziquantel as a positive control.

Other strategies have been used to decrease the infectivity of *D. caninum* eggs, with a study conducted in Brazil by Araujo *et al*⁽⁶⁹⁾ evaluating the effect of the nematophagous fungi *Poconia chlamydospora*, *Duddingtonia flagrans*, and *Monacrosporium thaumasium* on egg capsules. Their results showed that *Poconia chlamydospora* isolates had an ovicidal activity (type 2 and 3) for between 5 and 15 d after *in vitro* incubation. However, to date, the activity of a synthesized drug is found to have faster and more pronounced effects, as observed with the P-O treatment used in the present study.

Based on the results of the present study, P-O has *in vitro* cestocidal effects against the *D. caninum* tapeworm, showing a lethal effect and decreasing motility by 100 % within the first 6 h after *in vitro* incubation. Moreover, P-O has a direct effect on tegument thickness, reducing it by 42 %. The present study is the first conducted on the *in vitro* effects of P-O on mortality, the reduction of tegument thickness, and alterations in histological structures, such as the eggs, embryophore, embryo, and vitelline layer of the *D. caninum* tapeworm. The use of a P-O combination is an optional drug therapy for the control of *D. caninum* in naturally-infected dogs and cats.

Acknowledgements

The authors would like to thank the following: the Canine and Feline Control Center, Tlahuac, Mexico City, for the help in the collection of the small intestine samples from naturally-infected dogs; Maribel Nieto Miranda from the Faculty of Veterinary and Zoological Medicine at the National Autonomous University of Mexico (FMVZ-UNAM), for the great help with the histological procedures; to SEP-PROMEP for the financial support provided to Jair Millán-Orozco (School fee: 422006-0708) for the completion of the Master of Sciences at the Faculty of Agricultural and Livestock Sciences at the Autonomous University of the State of Morelos (FCA-UAEM); and, finally, to Adriana Silva de Oliveira for the technical assistance.

Conflicts of interest

The authors declare no conflict of interest.

Literature cited:

1. Dalimi A, Sattari A, Motamedi GH. A study on intestinal helminthes of dogs, foxes and jackals in the western part of Iran. *Vet Parasitol* 2006;142(1-2):129-133.
2. Hernández MR, Núñez FA, Pelayo DL. Potencial zoonótico de las infecciones por helmintos intestinales en perros callejeros de Ciudad de La Habana. *Rev Cub Med Trop* 2007;59(3):234-240.

3. Ziadinov I, Deplazes P, Mathis A, Mutunova B, Abdykerimov K, Nurgaziev R, Torgerson PR. Frequency distribution of *Echinococcus multilocularis* and other helminths of foxes in Kyrgyzstan. *Vet Parasitol* 2010;171(3-4):286-292.
4. Xhaxhiu D, Kusi I, Rapti D, Kondi E, Postoli R, Rinaldi L, *et al.* Principal intestinal parasites of dogs in Tirana, Albania. *Parasitol Res* 2011;108(2):341-353.
5. Cantó GJ, Guerrero RI, Olvera-Ramírez AM, Milián F, Mosqueda J, Aguilar-Tipacamú G. Prevalence of fleas and gastrointestinal parasites in free-roaming cats in Central Mexico. *Plos One* 2013;8(4):1-6.
6. Adolph C, Barnett S, Beall M, Drake J, Elsemore D, Thomas J, Little S. Diagnostic strategies to reveal covert infections with intestinal helminths in dogs. *Vet Parasitol* 2017;247:108-112. [dx.doi.org/10.1016/j.vetpar.2017.10.002](https://doi.org/10.1016/j.vetpar.2017.10.002).
7. Figueiredo PP, da Silva BA, Pereira de Moura AP, Leitão VM, Antunes UCA, Pereira BOM, Reis AMR. Gastrointestinal parasites in stray and shelter cats in the municipality of Rio de Janeiro, Brazil. *Braz J Vet Parasitol* 2017;26(3):383-388.
8. Molina CP, Ogburn J, Adegboyega P. Infection by *Dipylidium caninum* in an infant. *Arch Pathol Lab Med* 2003;127(3):157-159.
9. Bowman DD. *Georgis' Parasitología para Veterinarios*. 8ª ed. Madrid, España: Elsevier; 2004.
10. Charles SD, Altreuther G, Reinemeyer CR, Buch J, Settje T, Cruthers L, *et al.* Evaluation of the efficacy of emodepside+praziquantel topical solution against cestode (*Dipylidium caninum*, *Taenia taeniaeformis*, and *Echinococcus multilocularis*) infection in cats. *Parasitol Res* 2005;97(1):33-40.
11. Rodríguez-Vivas RI, Gutiérrez-Ruiz E, Bolio-González ME, Ruiz-Piña H, Ortega-Pacheco A, Reyes-Novelo E, *et al.* An Epidemiological study of intestinal parasites of dogs from Yucatan, Mexico, and their risk to public health. *Vector-Borne Zoon Dis* 2011;11(8):1141-1144.
12. Eguía-Aguilar P, Cruz-Reyes A, Martínez-Maya JJ. Ecological analysis and description of the intestinal helminths present in dogs in Mexico City. *Vet Parasitol* 2005;127(2):139-146.
13. Hendrix CM. *Diagnostic veterinary parasitology*. 2nd ed. St. Louis, MO, USA: Mosby; 1998.

14. Merchant MT, Aguilar L, Avila G, Robert L, Flisser A, Willms K. *Taenia solium*: description of the intestinal implantation sites in experimental hamster infections. *J Parasitol* 1998;84(4):681-685.
15. Domínguez MF, Koziol U, Porro V, Costábile A, Estrade S, Tort J, Bollati-Fologin F, Castillo E. A new approach for the characterization of proliferative cells in cestodes. *Exp Parasitol* 2014;138:25-29. [dx.doi.org/10.1016/j.exppara.2014.01.005](https://doi.org/10.1016/j.exppara.2014.01.005).
16. Martin RJ, Clark CL, Trailovic SM, Robertson AP. Oxantel is an N-type (methyridine and nicotine) agonist not an L-type (levamisole and pyrantel) agonist: classification of cholinergic anthelmintics in *Ascaris*. *Int J Parasitol* 2004;34(9):1083-1090.
17. McFarland JW, Howes HL. Novel anthelmintic agents. 6. Pyrantel analogues with activity against whipworm. *J Med Chem* 1972;15(4):365-368.
18. Robertson SJ, Pennington AJ, Evans AM, Martin RJ. The action of pyrantel as an agonist and an open channel blocker at acetylcholine receptors in isolated *Ascaris suum* muscle vesicles. *Eur J Pharmacol* 1994;271(2-3):273-282.
19. Kopp SR, Kotze AC, McCarthy JS, Traub RJ, Coleman GT. Pyrantel in small animal medicine: 30 years on. *Vet J* 2008;178(2):177-184.
20. Conti-Tronconi BM, McLane KE, Raftery MA, Grando SA, Protti MA. The nicotinic acetylcholine receptor: Structure and autoimmune pathology. *Crit Rev Biochem Mol Biol* 1994;29(2):69-123.
21. Robertson AP, Clark CL, Burns TA, Thompson DP, Geary TG, Trailovic SM, Martin RJ. Paraherquamide and 2-deoxyparaherquamide distinguish cholinergic receptor subtypes in *Ascaris* muscle. *J Pharmacol Exp Ther* 2002;302(3):853-860.
22. Martin RJ, Bai G, Clark CL, Robertson AP. Methyridine (2- [2-methoxyethyl]-pyridine) and levamisole activate different Ach receptor subtypes in nematode parasites: a new lead for levamisole resistance. *Brit J Pharm* 2003;140(6):1068-1076.
23. Howes Jr HL. Trans-1,4,5,6-tetrahydro-2-(3-hydroxystyryl)-1-methyl pyrimidine (CP-14,445), a new antiwhipworm agent. *Proc Soc Exp Biol Med* 1972;139:394-398.
24. Robinson M, Hooke F, Iverson KE. Efficacy of oxantel pamoate and pyrantel pamoate in combination against *Trichuris vulpis*, *Ancylostoma caninum* and *Toxocara canis* in dogs. *Aust Vet Pract* 1976;6:173-176.

25. Albonico M, Bickle Q, Haji HJ, Ramsan M, Khatib KJ, Montresor A, Savioli L, Taylor M. Evaluation of the efficacy of pyrantel-oxantel for the treatment of soil-transmitted nematode infections. *Trans R Soc Trop Med Hyg* 2002;96(6):685-690.
26. Millán OJ. Evaluación in vitro de cepas nativas de *Bacillus thuringiensis* contra el cestodo adulto de perros *Dipylidium caninum* [tesis maestría] Cuernavaca, Morelos, México: Facultad de Ciencias Agropecuarias, Universidad Autónoma del Estado de Morelos; 2009.
27. Khalifa RMA, Mazen NAM, Marawan AMA, Thabit HTM. Histochemical and ultrastructural studies on the calcareous corpuscles and eggs of *Taenia teaniformis* and *Dipylidium caninum*. *J Egypt Soc Parasitol* 2011;41(2):513-528.
28. Stepek G, Buttle DJ, Duce IR, Lowe A, Behnke JM. Assessment of the anthelmintic effect of natural plant cysteine proteinases against the gastrointestinal nematode, *Heligmosomoides polygyrus*, *in vitro*. *Parasitology* 2005;130(2):203-211.
29. Mansur F, Luoga W, Buttle DJ, Duce IR, Lowe A, Behnke JM. The anthelmintic efficacy of natural plant cysteine proteinases against two rodent cestodes *Hymenolepis diminuta* and *Hymenolepis microstoma* *in vitro*. *Vet Parasitol* 2014;201(1-2):48-58.
30. Mansur F, Luoga W, Buttle DJ, Duce IR, Lowe AE, Behnke JM. The anthelmintic efficacy of natural plant cysteine proteinases against the equine tapeworm, *Anoplocephala perfoliata* *in vitro*. *J Helminthol* 2016;90(5):561-568.
31. Flores-Pérez FI, de Aluja AS, Martínez-Maya JJ. Efectos en el desarrollo del metacestodo de *Taenia solium* inducidos por dosis bajas de radiación gamma. *Vet Méx* 2006;37(3):303-311.
32. Rosas-Velasco C, Pérez-Martínez M, Castillo-Juárez H, Flores-Pérez FI. Cambios histológicos inducidos por el acetato de medroxiprogesterona en el útero de conejas ovariectomizadas. *Vet Méx* 2007;38(2):207-214.
33. Peña G, Aguilar Jiménez FA, Hallal-Calleros C, Morales-Montor J, Hernández-Velázquez VM, Flores-Pérez FI. *In vitro* ovicidal and cestocidal effects of toxins from *Bacillus thuringiensis* on the canine and human parasite *Dipylidium caninum*. *BioMed Res Int* 2013. [dx.doi.org/10.1155/2013/174619](https://doi.org/10.1155/2013/174619).
34. Wayne WD. Bioestadística. Base para el análisis de las ciencias de la salud. 4ª ed. México, D.F: Limusa; 2006.
35. Martin RJ. Modes of action of anthelmintic drugs. *Vet J* 1997;154(1):11-34.

36. Hu Y, Xiao SH, Aroian RV. The new anthelmintic tribendimidine is an L-type (levamisole and pyrantel) nicotinic acetylcholine receptor agonist. *Plos Neglected Trop Dis* 2009;3(8):1-9.
37. Keiser J, Tritten L, Silbereisen A, Speich B, Adelfio R, Vargas M. Activity of oxantel pamoate monotherapy and combination chemotherapy against *Trichuris muris* and hookworms: Revival of an old drug. *Plos Neglected Trop Dis* 2013;7(3):1-8.
38. Choi WY, Lee OR, Lee WK, Kim WK, Chung CS, Ough BO. A clinical trial of Oxantel and Pyrantel against intestinal nematodes infections. *Korean J Parasitol* 1979;17(1):60-66.
39. Slocombe JOD. A modified critical test for the efficacy of pyrantel pamoate for *Anoplocephala perfoliata* in equids. *Can J Vet Res* 2004;68(2):112-117.
40. Marchiondo AA, White GW, Smith LL, Creinemeyer CR, Dascanio JJ, Johnson EG, Shugart JI. Clinical field efficacy and safety of pyrantel pamoate paste (19.13% w/w pyrantel base) against *Anoplocephala perfoliata* in naturally infected horses. *Vet Parasitol* 2006;137(1-2):94-102.
41. Reinemeyer CR, Hutchens DE, Eckblad WP, Marchiondo AA, Shugart JI. Dose-confirmation studies of the cestocidal activity of pyrantel pamoate paste in horses. *Vet Parasitol* 2006;138(3-4):234-239.
42. Reyes JL, González MI, Ledesma-Soto Y, Satoskar AR, Terrazas LI. TLR2 mediates immunity to experimental cysticercosis. *Int J Biol Sci* 2011;7(9):1323-1333.
43. Becker B, Mehlhorn H, Andrews P, Thomas H. Scanning and transmission electron microscope studies on the efficacy of praziquantel on *Hymenolepis nana* (Cestoda) *in vitro*. *Z Parasitenkd* 1980;61(2):121-133.
44. Mehlhorn H, Becker B, Andrews P, Thomas H. On the nature of the proglottids of cestodes: A light and electron microscopic study on *Taenia*, *Hymenolepis*, and *Echinococcus*. *Z Parasitenkd* 1981;65(3):243-259.
45. Becker B, Mehlhorn H, Andrews P, Thomas H. Ultrastructural investigations on the effect of praziquantel on the tegument of five species of Cestodes. *Z Parasitenkd* 1981;64(3):257-269.
46. Willms K, Robert L, Caro JA. Ultrastructure of smooth muscle, gap junctions and glycogen distribution in *Taenia solium* tapeworms from experimentally infected hamsters. *Parasitol Res* 2003;89(4):308-316.

47. Willms K, Robert L, Jiménez JA, Everhart M, Kuhn RE. Ultrastructure of spermiogenesis and the spermatozoon in *Taenia crassiceps* strobilae WFU strain (Cestoda, Cyclophyllidea, Taeniidae) from golden hamsters. *Parasitol Res* 2004;93:262-267. [dx.doi.org/10.1007/s00436-004-1125-5](https://doi.org/10.1007/s00436-004-1125-5).
48. Willms K, Robert L. Ultrastructure of a spermatid transport system in the mature proglottids of experimental *Taenia crassiceps* (WFU strain). *Parasitol Res* 2007;101:967-973. [dx.doi.org/10.1007/s00436-007-0570-3](https://doi.org/10.1007/s00436-007-0570-3).
49. Willms K, Zurabian R. *Taenia crassiceps*: *in vivo* and *in vitro* models. *Parasitology* 2010;137(3):335-346.
50. Maggiore M, Elisondo MC. *In vitro* cestocidal activity of thymol on *Mesocestoides corti* Tetrathyridia and adult worms. *Interdisciplinary Perspectives on Infect Dis* 2014. [dx.doi.org/10.1155/2014/268135](https://doi.org/10.1155/2014/268135).
51. Tandon V, Pal P, Roy B, Rao HSP, Reddy KS. In vitro anthelmintic activity of root-tuber extract of *Flemingia vestita*, an indigenous plant in Shillong, India. *Parasitol Res* 1997;83(5):492-498.
52. Roy B, Dasgupta S, Tandon V. Ultrastructural observations on tegumental surface of *Raillietina echinobothrida* and its alterations caused by root-peel extract of *Millettia pachycarpa*. *Microscopy Res Tech* 2008;71(1):810-815.
53. Challam M, Roy B, Tandon V. Effect of *Lysimachia ramosa* (Primulaceae) on helminth parasites: Motility, mortality and scanning electron microscopic observations on surface topography. *Vet Parasitol* 2010;169(1-2):214-218.
54. Dasgupta S, Roy B, Tandon V. Ultrastructural alterations of the tegument of *Raillietina echinobothrida* with the stem bark of *Acacia oxyphylla* (Leguminosae). *J Ethnopharmacol* 2010;127(2):568-571.
55. Meaney M, Fairweather I, Brennan GP, Forbes AB. Transmission electron microscope study of the ultrastructural changes induced in the tegument and gut of *Fasciola hepatica* following *in vivo* drug treatment with clorsulon. *Parasitol Res* 2004;92:232-241. [dx.doi.org/10.1007/s00436-003-1036-x](https://doi.org/10.1007/s00436-003-1036-x).
56. Roy B, Tandon V. Effect of root-tuber extract of *Flemingia vestita*, a leguminous plant, on *Artyfechinostomum sufrartyfex* and *Fasciolopsis buski*: A scanning electron microscopy study. *Parasitol Res* 1996;82:248-252. [dx.doi.org/10.1007/s004360050104](https://doi.org/10.1007/s004360050104).

57. Stepek G, Lowe AE, Buttle DJ, Duce IR, Behnke JM. *In vitro* anthelmintic effects of cysteine proteinases from plants against intestinal helminths of rodents. *J Helminthol* 2007;81(4):353-360.
58. Stepek G, Lowe AE, Buttle DJ, Duce IR, Behnke JM. *In vitro* and *in vivo* anthelmintic efficacy of plant cysteine proteinases against the rodent gastrointestinal nematode, *Trichuris muris*. *Parasitology* 2006;132(5):681-689.
59. Stepek G, Lowe AE, Buttle DJ, Duce IR, Behnke JM. The anthelmintic efficacy of plant-derived cysteine proteinases against the rodent gastrointestinal nematode, *Heligmosomoides polygyrus*, *in vivo*. *Parasitology* 2007;134(10):1409-1419.
60. Stepek G, Curtis RHC, Kerry BR, Shewry PR, Clark SJ, Lowe AE, Duce IR, Buttel DJ, Behnke JM. Nematicidal effects of cysteine proteinases against sedentary plant parasitic nematodes. *Parasitology* 2007;134(12):1831-1838.
61. Chalar C, Salomé M, Señolare-Pose M, Marín M, Williams CT, Dauphin Y. A high resolution analysis of the structure and chemical composition of the calcareous corpuscles from *Mesocestoides corti*. *Micron* 2013;44:185-192. [dx.doi.org/10.1016/j.micron.2012.06.008](https://doi.org/10.1016/j.micron.2012.06.008).
62. Etges FJ, Marinakis V. Formation and excretion of calcareous bodies by the metacestode (Tetrathyridium) of *Mesocestoides vogae*. *J Parasitol* 1991;77(4):595-602.
63. Vargas-Parada L, Laclette JP. Role of calcareous corpuscles in cestode physiology: A review. *Rev Latinoam Microbiol* 1999;41(4):303-307.
64. Khin SS, Kitazawa R, Htet K, Htike HM, Yee TT, Aung M, Haraguchi R, Kitazawa S. Intestinal inflammatory pseudotumor caused by taeniasis: Calcareous corpuscles as a diagnostic clue. *Pathol Int* 2013;63(3):193-194.
65. Loos JA, Caparros PA, Nicolao MC, Denegri GM, Cumino AC. Identification and pharmacological induction of autophagy in the larval stages of *Echinococcus granulosus*: an active catabolic process in calcareous corpuscles. *Int J Parasitol* 2014;44(4):415-427.
66. Yang HJ. Immunoblot findings of calcareous corpuscles binding proteins in cyst fluid of *Taenia solium* metacestode. *Korean J Parasitol* 2004;42(3):141-143.
67. Park YK, Park JH, Guk SM, Shin EH, Chai JY. A new method for concentration of proteins in the calcareous corpuscles separated from the spargana of *Spirometra erinacei*. *Korean J Parasitol* 2005;43(3):119-122.

68. Willms K, Fernández PAM, Jiménez JA, Landa A, Zurabián R, Juárez UME, Robert L. Taeniid tapeworm responses to *in vitro* glucose. *Parasitol Res* 2005;96: 296-301. [dx.doi.org/10.1007/s00436-005-1348-0](https://doi.org/10.1007/s00436-005-1348-0).
69. Araujo JM, de Araújo JV, Braga FR, Carvalho RO, Ferreira SR. Activity of the nematophagous fungi *Poconia chlamydospora*, *Duddingtonia flagrans* and *Monacrosporium thaumasium* on egg capsules of *Dipylidium caninum*. *Vet Parasitol* 2009;166(1-2):86-89.